



The Non-Ossifying Fibroma: A Case Report and Review of the Literature

Shengjie Sun, Weixiong Ye, Yangyang Xu, Zhencheng Feng*, Qingqi Meng*

Department of Orthopedics, Guangzhou Red Cross Hospital, Jinan University, Guangzhou, China

Email address:

916649827@qq.com (Shengjie Sun), 893846791@qq.com (Zhencheng Feng), meng_qingqi@126.com (Qingqi Meng)

*Corresponding author

To cite this article:

Shengjie Sun, Weixiong Ye, Yangyang Xu, Zhencheng Feng, Qingqi Meng. The Non-Ossifying Fibroma: A Case Report and Review of the Literature. *Journal of Surgery*. Vol. 10, No. 4, 2022, pp. 140-143. doi: 10.11648/j.js.20221004.12

Received: August 31, 2022; **Accepted:** September 12, 2022; **Published:** September 27, 2022

Abstract: Nonossifying fibroma is a benign tumor lesion commonly seen in children that is characterized by spontaneous regression and is usually located in the cortex of long bones, but cases occurring in other bone tissues have also been reported. It is usually not accompanied by clinical manifestations such as pain and dysfunction of the affected limb throughout the course of the disease, and the shape of the same affected limb is not significantly changed, usually found by imaging examination after injury. In this paper, we report a 12-year-old male patient who was admitted to our hospital with left lower leg pain caused by a fall during running. Emergency radiography of the left leg showed cystic swelling lesion in the cortex at the anterior edge of the left tibial metaphysis, aneurysmal bone cyst? non-ossifying fibroma? Relevant preoperative examinations were perfected after admission, and through adequate preoperative planning and discussion, it was decided to perform debridement and bone grafting of the left lower tibial tumor lesion. After operation, the function of left lower limb recovered well after professional rehabilitation training, and the therapeutic effect was satisfactory. When imaging studies after injury suspect uncured fibroma or pathological fractures, debridement and bone grafting of the lesion is necessary to prevent further aggravation of the fracture.

Keywords: Non Ossifying Fibroma, Children Bone Tumour, Pediatrics, Surgical Treatment, Unusual Presentation

1. Introduction

Non-ossifying fibroma is the most common benign lesion in the skeletal system of adolescents under 15 years of age [1]. According to statistics, about 30 to 40% of children develop one or more non-ossifying fibroma during skeletal development [2], with insidious onset and no clinical manifestations during the period. Only a few lesions are large and may be accompanied by pain in the affected limb, usually found incidentally, most commonly in the distal femur, proximal and distal tibia, fibula, proximal humerus and radius [3]. The identified causes may be related to gene mutations. Although the onset is insidious and not accompanied by clinical symptoms, the diagnosis of the disease is complex and can be confirmed by its imaging findings and characteristic pathological findings.

In this study, we report a case of NOF found in the left

tibia of a 12-year-old man and review the imaging, clinical, and histological features of this unusual disease.

2. Case Presentation

A 12-year-old male patient developed distal pain in his left calf after exercise 6 days before admission, which was relieved after rest. The site of pain is slightly swollen, tender, no increase in skin temperature, no superficial ulceration. X-rays performed in outpatient clinics in other hospitals suggest that pathological fractures of the lower tibial cysts of the left tibia and its anterior wall may be performed without special treatment. For further treatment, visit our orthopedic clinic. The physical examination found that the lower part of the left calf was obviously tender, percussion, swelling, no increase in local skin

temperature, and no rupture of the surrounding skin. There is no obvious restriction on the flexion and extension of the left ankle, the flexion and extension of the left toe can be moved, and there is no abnormality in the sensation and blood transport of the left lower limb. After admission, no obvious abnormalities were found in blood routine, urine routine, C-reactive protein, blood biochemistry, and liver and kidney function. Chest x-ray, electrocardiogram, and preoperative results were normal. Left ankle x-ray (Figure 1) showing corticocystic swelling lesions at the anterior edge of the epiphyseal end of the lower tibia on the left side, aneurysm-like bone cyst? Non-ossified fibromas? A flat scan of the left ankle and enhanced MRI (Figure 2) shows that the anterior cortex of the left tibia is visible, about 3.5×1.5 cm in size, mildly inflated, surrounded by a ring of lower signal hardening edges, mildly unevenly strengthened by the contrast scan, and the leading bone cortex is not continuous. No clear abnormalities were seen in the remaining scans and bones of the left ankle, no edema and mass lesions were seen in the surrounding soft tissues, and no clear abnormal reinforcement was seen on the enhancement scan. To further clarify the diagnosis and treatment; Electively underwent sub-tibia tumor lesion removal + bone grafting in the lower tibial section of the left side under external durarian anesthesia in the operating room. After successful anesthesia, the patient lies on his back in a position with his left hip raised. Tourniquet of the air sac on the left thigh. The left lower limb is sterilized with iodine and alcohol, and a sterile towel sheet is laid, and a longitudinal straight incision is made on the fibula side of the tibia ridge in the lower part of the lower leg, which is about 5 cm long. Cut the skin, subcutaneous tissue, deep fascia, and extensor support band, pull the anterior tibia tendon to the fibula side, and cut the periosteum longitudinally, revealing the distal tibial tumor bulge site. After fluoroscopic localization, a $20 \text{ mm} \times 10 \text{ mm}$ bone window is opened in the anterior tibia cortex. Opening the bone window to investigate, it was found that the tumor bone cystic cavity was filled with yellow-brown granulation-like tissue, and the bone sclerosis of the inner wall of the tumor cystic cavity. Removal of tumor tissue in the cystic cavity. After irrigating the cystic cavity, the cyst cavity is filled with allogeneic cancellous bone and self-curing calcium phosphate granules. The bone fragments are reduced, the periosteum and extensor support band are repaired, the incision is closed, and the ankle is fixed in a neutral position with a cast post-cast. Histopathological display of postoperative patients (Figure 3): "left tibia" non-ossified fibroma. After the operation, the pain in the left lower extremity of the patient improved significantly. During the 12 months postoperative follow-up period, there was no pain in the left lower extremity, and the left lower extremity was moving as usual. Re-examination of the tibial x-ray showed that we followed up for another six months, during which there was no left lower extremity pain or recurrence of non-ossified fibroma.

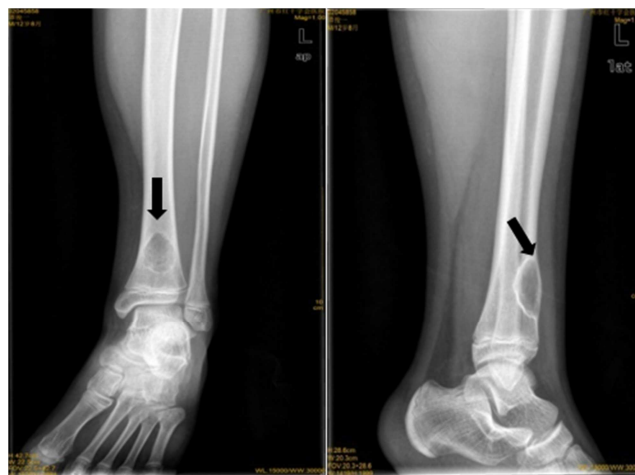


Figure 1. The left ankle x-ray.

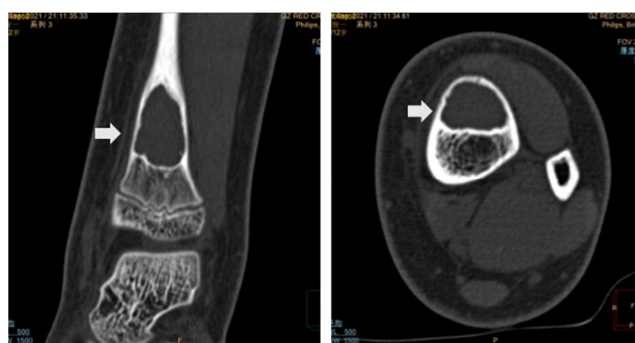


Figure 2. The left ankle and enhanced MRI.

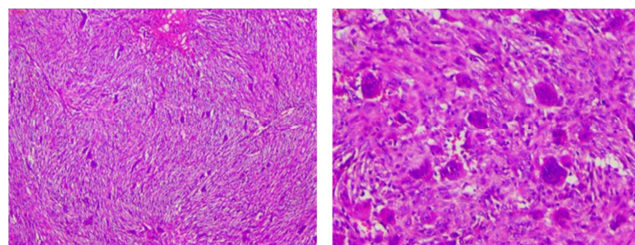


Figure 3. Histopathological display of postoperative patients.

3. Conclusion

In this paper, the clinical manifestations, imaging, and histopathological features of a 12-year-old Chinese adolescent with a non-ossified fibroma of the left tibia are reported. It is a disease with a long history [4], Before the final name of non-ossified fibroma, with the further development of related research on this disease, and according to the characteristics of the lesion process, the name of this lesion has also changed, such as histiocytic fibrous defects, epiphyseal fibrous defects, fibrocortical defects [5], fibrox xanthelama and histiocytic yellow granulomas [6]. However, the two terms most commonly used to describe these lesions to date are "fibrocortical defect" (FCD) and "non-ossification fibroma" (NOF) [7]. The two are actually different time periods of the same lesion, the difference is whether it invades the medullary cavity and the lesion range is more than 3 cm, invading it

to become a non-ossified fibroma, and vice versa, it becomes a fibrocortical defect [8]. Nonossified fibroids occur mainly in adolescents under 15 years of age, with the highest incidence in children aged 4 to 8 years, and non-ossified fibroids with long bones are more common in men [2, 9]. Diagnosis of NOF is generally based on imaging findings and, rarely, chronic pain or occasional pathological fractures. Imaging presentation of NOF is generally clearly defined and oval at the epiphyseal end of the long shaft, usually without periosteal reactions and without significant osteolytic changes of bone destruction [3]. Most NOFs also decompose spontaneously, but due to their large size, it usually takes longer than FCD, and radiologically observes a "regression" of the degenerative phase as a lesion: the trabecular bone appears to grow inward from the periphery until the bone returns to its normal state [10]. A retrospective analysis of 16 non-ossified fibroids showed that this spontaneous regression has been suggested to be associated with increased endocrine regulation of adolescent estrogen through ERalpha receptor signaling, and whether adolescent estrogen signaling is involved in inducing aging of NOF tumor cells containing mutations in the RAS/MAPK pathway needs to be further explored [11]. In a recent article in the Journal of Pathology, Baumhoer and colleagues demonstrated that 80 percent of non-ossified fibroids have mutations that activate the RAS-MAPK pathway (KRAS, FGFR1, and NF1), and their findings suggest that NOFs, long considered reactive, should be considered true tumors, and that the results of this mutation may be temporary based on the pathological features of NOFs that are benign lesions and self-limiting. Or not enough to promote the sustained growth of tumor cells, so that the lesion may "fade" at a certain stage of development [12]. Similar to NOF, dimensional dysplasia, a bone fiber-bone lesion caused by a GNAS mutation embedded in osteoblast premise, with a final outcome similar to THATF, usually matures in the patient's skeletal system, fibrotic dysplasia lesions stop growing, and eventually grow from granulation tissue, then polarized and mineralized. Eventually, GNAS mutations can no longer be detected, which can be explained in terms of progressive apoptosis of mutated cells [13]. It has been speculated that the regression of NOF can also be explained by this mechanism, or that low-frequency KRAS and FGFR1 mutations have only a small number of diseased cells. Rare reports in the adult NOF literature suggest that most lesions also resolve spontaneously over time [14]. Although there have been reports of a case of NOF in the tibia that has been malignantly transformed into invasive fibrosarcoma [14], But the postoperative process is usually safe [15]. Because the disease resolves with age, pathological fractures secondary to NOF are also rare and do not require surgery in most cases, but surgery may be reasonable. When there are painful symptoms, it is considered to be at risk of pathological fractures [16]. Surgery can prevent pathological fractures and improve

pain symptoms and potentially pathological fractures in some patients [17].

References

- [1] Baumhoer D, Rogozhin D. WHO Classification of Tumours of Soft Tissue and Bone. 5: Lyon: IARC Press, 2020.
- [2] Nielsen G P, Kyriakos M. Non-ossifying fibroma/benign fibrous histiocytoma of bone [J], 2013.
- [3] Mankin H J, Trahan C A, Fondren G, et al. Non-ossifying fibroma, fibrous cortical defect and Jaffe-Campanacci syndrome: a biologic and clinical review [J]. La Chirurgia Degli Organi Di Movimento, 2009, 93 (1): 1-7.
- [4] Sontag L W, Pyle S I. The appearance and nature of cyst-like areas in the distal femoral metaphysis of children [J]. American Journal of Roentgenology, 1941, 46: 185-188.
- [5] Chrcanovic B R, Albanese A L, Freire-Maia B, et al. Non-ossifying fibroma (metaphyseal fibrous defect) of the mandible [J]. Oral and maxillofacial surgery, 2011, 15 (4): 233-237.
- [6] Weiss S, Bridge J. World Health Organization Classification of Tumours, Pathology & Genetics Tumours of Soft Tissue and Bone: IARC Press, Lyon, 2002.
- [7] Dahlin D. Fibroma (nonosteogenic fibroma of bone, metaphyseal fibrous defect), myxoma, cortical desmoid, fibromatosis, and "anthoma"[J]. Bone tumors. general aspects and data on, 1978, 6: 122-36.
- [8] Klein M H, Rosenberg Z S, Lehman W. Nonossifying fibroma of bone: a case report [J]. Bulletin of the Hospital for Joint Diseases Orthopaedic Institute, 1990, 50 (1): 64-69.
- [9] Betsy M, Kupersmith L M, Springfield D S. Metaphyseal fibrous defects [J]. The Journal of the American Academy of Orthopaedic Surgeons, 2004, 12 (2): 89-95.
- [10] Mirra J M. Fibrohistiocytic tumors of intramedullary origin [J], 1989.
- [11] Cleven A H G, Schreuder W H, Groen E, et al. Oestrogen receptor expression distinguishes non-ossifying fibroma from other giant cell containing bone tumours [J]. Virchows Archiv: an International Journal of Pathology, 2022.
- [12] Baumhoer D, Kovac M, Sperveslage J, et al. Activating mutations in the MAP-kinase pathway define non-ossifying fibroma of bone [J]. The Journal of Pathology, 2019, 248 (1): 116-122.
- [13] Kuznetsov S A, Cherman N, Riminucci M, et al. Age-dependent demise of GNAS-mutated skeletal stem cells and "normalization" of fibrous dysplasia of bone [J]. Journal of Bone and Mineral Research: the Official Journal of the American Society For Bone and Mineral Research, 2008, 23 (11): 1731-1740.
- [14] Blau R A, Zwick D L, Westphal R A. Multiple non-ossifying fibromas. A case report [J]. Journal of Bone & Joint Surgery American Volume, 1988, 70 (2): 299-304.
- [15] Mizukawa N, Nishijima Y, Nishijima K. Metaphyseal fibrous defect (nonossifying fibroma) in the mandible. A case report [J]. International Journal of Oral & Maxillofacial Surgery, 1997, 26 (2): 129.

- [16] Canavese F, Samba A, Rousset M. Pathological fractures in children: Diagnosis and treatment options [J]. Orthopaedics & Traumatology, Surgery & Research: OTSR, 2016, 102 (1 Suppl): S149-S159.
- [17] Cherix S, Bildé Y, Becce F, et al. Multiple non-ossifying fibromas as a cause of pathological femoral fracture in Jaffe-Campanacci syndrome [J]. BMC Musculoskeletal Disorders, 2014, 15: 218.